

What's Eating You? Human Body Lice (*Pediculus humanus corporis*)

Emily S. Nyers, MD; Dirk M. Elston, MD

PRACTICE POINTS

- Body lice reside in clothing, particularly folds and seams, and migrate to the host for blood meals. To evaluate for infestation, the clinician should not only look at the skin but also closely examine the patient's clothing. Clothes also are a target for treatment via washing in hot water.
- Due to observed and theoretical adverse effects of other chemical treatments, benzyl alcohol is the authors' choice for treatment of head lice.
- Oral ivermectin is a promising future treatment for body lice.

Compared to head and pubic lice, body lice (*Pediculus humanus corporis*) carry increased morbidity in the form of greater body surface area involvement, possible infectious disease transmission, and the potential for secondary iron-deficiency anemia. They thrive in high-density urban populations in which hygiene is poor, such as among the homeless. Treatment includes washing of affected individuals, their possessions, and treatment with topical insecticides. Growing patterns of treatment resistance seen in body lice necessitate development of new strategies, with oral medications serving as a promising option.

Cutis. 2020;105:118-120.

Epidemiology and Transmission

Pediculus humanus corporis, commonly known as the human body louse, is one in a family of 3 ectoparasites of the same suborder that also encompasses pubic lice (*Phthirus pubis*) and head lice (*Pediculus humanus capitis*). Adults are approximately 2 mm in size, with the

same life cycle as head lice (Figure 1). They require blood meals roughly 5 times per day and cannot survive longer than 2 days without feeding.¹ Although similar in structure to head lice, body lice differ behaviorally in that they do not reside on their human host's body; instead, they infest the host's clothing, localizing to seams (Figure 2), and migrate to the host for blood meals. In fact, based on this behavior, genetic analysis of early human body lice has been used to postulate when clothing was first used by humans as well as to determine early human migration patterns.^{2,3}

Although clinicians in developed countries may be less familiar with body lice compared to their counterparts, body lice nevertheless remain a global health concern in impoverished, densely populated areas, as well as in homeless populations due to poor hygiene.

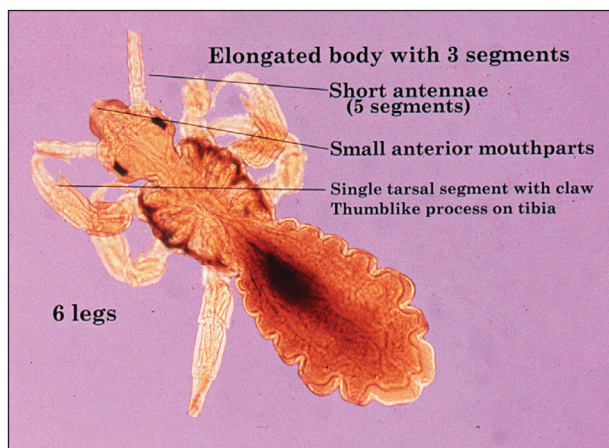


FIGURE 1. Adult body louse (*Pediculus humanus corporis*).

From the Medical University of South Carolina, Charleston. Dr. Nyers is from the Department of Internal Medicine, and Dr. Elston is from the Department of Dermatology and Dermatologic Surgery.

The authors report no conflict of interest.

Images are in the public domain.

Correspondence: Emily S. Nyers, MD, 135 Rutledge Ave, MSC 578, Charleston, SC 29425 (nyers@musc.edu).

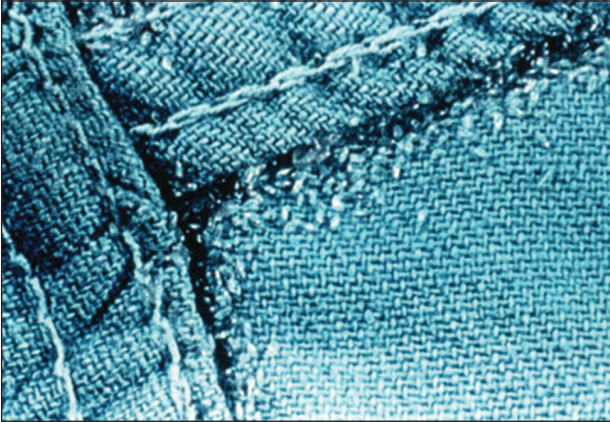


FIGURE 2. Body lice nits localized in clothing seams.

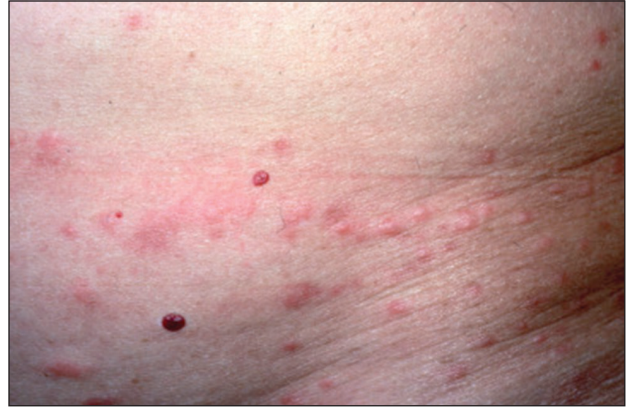

FIGURE 3. Erythematous papules secondary to body lice infestation.

Transmission frequently occurs via physical contact with an affected individual and his/her personal items (eg, linens) via fomites.^{4,5} Body louse infestation is more prevalent in homeless individuals who sleep outside vs in shelters; a history of pubic lice and lack of regular bathing have been reported as additional risk factors.⁶ Outbreaks have been noted in the wake of natural disasters, in the setting of political upheavals, and in refugee camps, as well as in individuals seeking political asylum.⁷ Unlike head and pubic lice, body lice can serve as vectors for infectious diseases including *Rickettsia prowazekii* (epidemic typhus), *Borrelia recurrentis* (louse-borne relapsing fever), *Bartonella quintana* (trench fever), and *Yersinia pestis* (plague).^{5,8,9} Several *Acinetobacter* species were isolated from nearly one-third of collected body louse specimens in a French study.¹⁰ Additionally, serology for *B quintana* was found to be positive in up to 30% of cases in one United States urban homeless population.⁴

Clinical Manifestations

Patients often present with generalized pruritus, usually considerably more severe than with *P humanus capitis*, with lesions concentrated on the trunk.¹¹ In addition to often impetiginized, self-inflicted excoriations, feeding sites may present as erythematous macules (Figure 3), papules, or papular urticaria with a central hemorrhagic punctum. Extensive infestation also can manifest as the colloquial vagabond disease, characterized by postinflammatory hyperpigmentation and thickening of the involved skin. Remarkably, patients also may present with considerable iron-deficiency anemia secondary to high parasite load and large volume blood feeding. Multiple case reports have demonstrated associated morbidity.¹²⁻¹⁴ The differential diagnosis for pediculosis may include scabies, lichen simplex chronicus, and eczematous dermatitis, though the clinician should prudently consider whether both scabies and pediculosis may be present, as coexistence is possible.^{4,15}

Diagnosis

Diagnosis can be reached by visualizing adult lice, nymphs, or viable nits on the body or more commonly within inner clothing seams; nits also fluoresce under Wood light.¹⁵ Although dermoscopy has proven useful for increased sensitivity and differentiation between viable and hatched nits, the insects also can be viewed with the unaided eye.¹⁶

Treatment: New Concerns and Strategies

The mainstay of treatment for body lice has long consisted of thorough washing and drying of all clothing and linens in a hot dryer. Treatment can be augmented with the addition of pharmacotherapy, plus antibiotics as warranted for louse-borne disease. Pharmacologic intervention often is used in cases of mass infestation and is similar to head lice.

Options for head lice include topical permethrin, malathion, lindane, spinosad, benzyl alcohol, and ivermectin. Pyrethroids, derived from the chrysanthemum, generally are considered safe for human use with a side-effect profile limited to irritation and allergy¹⁷; however, neurotoxicity and leukemia are clinical concerns, with an association more recently shown between large-volume use of pyrethroids and acute lymphoblastic leukemia.^{18,19} Use of lindane is not recommended due to a greater potential for central nervous system neurotoxicity, manifested by seizures, with repeated large surface application. Malathion is problematic due to the risk for mucosal irritation, flammability of some formulations, and theoretical organophosphate poisoning, as its mechanism of action involves inhibition of acetylcholinesterase.¹⁵ However, in the context of head lice treatment, a randomized controlled trial reported no incidence of acetylcholinesterase inhibition.²⁰ Spinosad, manufactured from the soil bacterium *Saccharopolyspora spinosa*, functions similarly by interfering with the nicotinic acetylcholine receptor and also carries a risk for skin irritation.²¹ Among all the treatment options, we prefer benzyl alcohol, particularly in the context of resistance, as it is effective via a physical

mechanism of action and lacks notable neurotoxic effects to the host. Use of benzyl alcohol is approved for patients as young as 6 months; it functions by asphyxiating the lice via paralysis of the respiratory spiracle with occlusion by inert ingredients. Itching, episodic numbness, and scalp or mucosal irritation are possible complications of treatment.²²

Treatment resistance of body lice has increased in recent years, warranting exploration of additional management strategies. Moreover, developing resistance to lindane and malathion has been reported.²³ Resistance to pyrethroids has been attributed to mutations in a voltage-gated sodium channel, one of which was universally present in the sampling of a single population.²⁴ A randomized controlled trial showed that off-label oral ivermectin 400 µg/kg was superior to malathion lotion 0.5% in difficult-to-treat cases of head lice²⁵; utility of oral ivermectin also has been reported in body lice.²⁶ In vitro studies also have shown promise for pursuing synergistic treatment of body lice with both ivermectin and antibiotics.²⁷

A novel primary prophylaxis approach for at-risk homeless individuals recently utilized permethrin-impregnated underwear. Although the intervention provided short-term infestation improvement, longer-term use did not show improvement from placebo and also increased prevalence of permethrin-resistant haplotypes.²⁸

REFERENCES

- Veracx A, Raoult D. Biology and genetics of human head and body lice. *Trends Parasitol.* 2012;28:563-571.
- Kittler R, Kayser M, Stoneking M. Molecular evolution of *Pediculus humanus* and the origin of clothing. *Curr Biol.* 2003;13:1414-1417.
- Drali R, Mumcuoglu KY, Yesilyurt G, et al. Studies of ancient lice reveal unsuspected past migrations of vectors. *Am J Trop Med Hyg.* 2015;93:623-625.
- Chosidow O. Scabies and pediculosis. *Lancet.* 2000;355:819-826.
- Feldmeier H, Heukelbach J. Epidermal parasitic skin diseases: a neglected category of poverty-associated plagues. *Bull World Health Organ.* 2009;87:152-159.
- Arnaud A, Chosidow O, Detrez MA, et al. Prevalence of scabies and *Pediculosis corporis* among homeless people in the Paris region: results from two randomized cross-sectional surveys (HYTPEAC study). *Br J Dermatol.* 2016;174:104-112.
- Hytonen J, Khawaja T, Gronroos JO, et al. Louse-borne relapsing fever in Finland in two asylum seekers from Somalia. *APMIS.* 2017;125:59-62.
- Nordmann T, Feldt T, Bosselmann M, et al. Outbreak of louse-borne relapsing fever among urban dwellers in Arsi Zone, Central Ethiopia, from July to November 2016. *Am J Trop Med Hyg.* 2018;98:1599-1602.
- Louni M, Mana N, Bitam I, et al. Body lice of homeless people reveal the presence of several emerging bacterial pathogens in northern Algeria. *PLoS Negl Trop Dis.* 2018;12:E0006397.
- Candy K, Amanzougaghene N, Izri A, et al. Molecular survey of head and body lice, *Pediculus humanus*, in France. *Vector Borne Zoonotic Dis.* 2018;18:243-251.
- Bolognia JL, Schaffer JV, Cerroni L. *Dermatology.* 4th ed. Elsevier Limited; 2018.
- Nara A, Nagai H, Yamaguchi R, et al. An unusual autopsy case of lethal hypothermia exacerbated by body lice-induced severe anemia. *Int J Legal Med.* 2016;130:765-769.
- Althomali SA, Alzubaidi LM, Alkhalidi DM. Severe iron deficiency anaemia associated with heavy lice infestation in a young woman [published online November 5, 2015]. *BMJ Case Rep.* doi:10.1136/bcr-2015-212207.
- Hau V, Muhi-Iddin N. A ghost covered in lice: a case of severe blood loss with long-standing heavy pediculosis capitis infestation [published online December 19, 2014]. *BMJ Case Rep.* doi:10.1136/bcr-2014-206623.
- Diaz JH. Lice (Pediculosis). In: *Mandell, Douglas, and Bennett's Principles and Practice of Infectious Diseases.* 9th ed. New York, NY: Elsevier; 2020:3482-3486.
- Martins LG, Bernardes Filho F, Quaresma MV, et al. Dermoscopy applied to pediculosis corporis diagnosis. *An Bras Dermatol.* 2014; 89:513-514.
- Devore CD, Schutze GE; Council on School Health and Committee on Infectious Diseases, American Academy of Pediatrics. Head lice. *Pediatrics.* 2015;135:E1355-E1365.
- Shafer TJ, Meyer DA, Crofton KM. Developmental neurotoxicity of pyrethroid insecticides: critical review and future research needs. *Environ Health Perspect.* 2005;113:123-136.
- Ding G, Shi R, Gao Y, et al. Pyrethroid pesticide exposure and risk of childhood acute lymphocytic leukemia in Shanghai. *Environ Sci Technol.* 2012;46:13480-13487.
- Meinking TL, Vicaria M, Eyerdam DH, et al. A randomized, investigator-blinded, time-ranging study of the comparative efficacy of 0.5% malathion gel versus Ovide Lotion (0.5% malathion) or Nix Crème Rinse (1% permethrin) used as labeled, for the treatment of head lice. *Pediatr Dermatol.* 2007;24:405-411.
- McCormack PL. Spinosad: in pediculosis capitis. *Am J Clin Dermatol.* 2011;12:349-353.
- Meinking TL, Villar ME, Vicaria M, et al. The clinical trials supporting benzyl alcohol lotion 5% (Ulesfia): a safe and effective topical treatment for head lice (pediculosis humanus capitis). *Pediatr Dermatol.* 2010;27:19-24.
- Lebwohl M, Clark L, Levitt J. Therapy for head lice based on life cycle, resistance, and safety considerations. *Pediatrics.* 2007;119: 965-974.
- Drali R, Benkouiten S, Badiaga S, et al. Detection of a knockdown resistance mutation associated with permethrin resistance in the body louse *Pediculus humanus corporis* by use of melting curve analysis genotyping. *J Clin Microbiol.* 2012;50:2229-2233.
- Chosidow O, Giraudeau B, Cottrell J, et al. Oral ivermectin versus malathion lotion for difficult-to-treat head lice. *N Engl J Med.* 2010;362:896-905.
- Foucault C, Ranque S, Badiaga S, et al. Oral ivermectin in the treatment of body lice. *J Infect Dis.* 2006;193:474-476.
- Sangaré AK, Doumbo OK, Raoult D. Management and treatment of human lice [published online July 27, 2016]. *Biomed Res Int.* doi:10.1155/2016/8962685.
- Benkouiten S, Drali R, Badiaga S, et al. Effect of permethrin-impregnated underwear on body lice in sheltered homeless persons: a randomized controlled trial. *JAMA Dermatol.* 2014;150:273-279.